

**Complex Regional Pain Syndrome (CRPS) and Spinal Cord Stimulator (SCS)**  
**H. Hooshmand, M.D. and Eric M. Phillips**  
**Neurological Associates Pain Management Center**  
**Vero Beach, Florida**

***Abstract.** The following is a summary of our experience with treating complex regional pain syndrome (CRPS) patients who have undergone spinal cord stimulator (SCS) treatment for one year or longer. The success or failure of the treatment with SCS depends on how early in the course of the illness the SCS treatment started, and depends on the nature of the original nociceptive pain.*

***Descriptors.** complex regional pain syndrome (CRPS), failed back syndrome (FBS), failed neck syndrome (FNS), infrared thermal imaging (ITI), spinal cord stimulator (SCS).*

### **INTRODUCTION**

Spinal cord stimulators (SCS) are effective in treatment of somatic chronic pain (e.g., failed back syndrome (FBS) and failed neck syndrome (FNS)) but it does not help CRPS patients. Usually, the beneficial effect of SCS in management of CRPS is brief (a few weeks to a few months in more than 70% of patients). The SCS as a foreign body, may aggravate the CRPS pain, cause vasoconstriction, and inflammation in late stages of CRPS. Interferential surface skin stimulator, a modified form of transcutaneous electrical nerve stimulation (TENS), is a good non-invasive substitute.

In our experience, the type of patient that we see in our clinic is different from most other centers. The patients that end up in our clinic have been to primary, and secondary referral centers. We are a tertiary center of the last resort where late stage CRPS patients are treated. Most of the patients that we receive already have had on the average of one to two surgical procedures, e.g., carpal tunnel syndrome and SCS treatment, and in many cases more. The majority of the cases who have had SCS treatments have had the original invasive procedure plus revisions, replacements, or the adjustments of the position of the electrodes, etc.

To begin with, we have to divide the effect of CRPS into two separate types of nociceptive pain, i.e., somesthetic pain such as FBS, versus neuropathic pain such as CRPS. The neuropathic pain has a neurovascular component to it whereas the somesthetic pain usually does not have a neurovascular component.

SCS is a digital stimulator utilized for treatment of an analog symptom (the analog pain modality is random and not time locked or digital). It is not a type of treatment that would be successful in every form of chronic pain.

In CRPS, the immune system is rogue. This is because the immune system is modulated by the sympathetic system. The sympathetic system, under pain input, responds by releasing T-cell lymphocytes (in early stages CD4 or helper lymphocytes, and in late stages CD8 or killer T-cell lymphocytes)(1,2). So, after the SCS has lost its effect, the sympathetic system considers the foreign body of the SCS as a source of sympathetic dysfunction. This causes neuroinflammation manifested as skin rash, edema, and infection(1,3).

## CASE REPORT

A 32-year-old police woman while on duty was chasing two criminals. One of the criminals was obviously an expert in shooting, and shot the police woman in both legs. She developed severe CRPS because of this incident. A small fragment of the bullet in the left leg was not able to be removed surgically because it was too close to the sciatic nerve that the surgeon decided not to disrupt the circulation in that area.

Because of the severity of the pain, four months after the injury, the patient had received an SCS implant. Every time the SCS was turned on, the patient would develop a moderate edema of the left lower extremity, edema and water retention (serous fluid) under the scar of the SCS insertion, and she would have severe electric shock feeling in the left lower extremity in the area of the bullet scar. The patient complained of severe chest pain and dizziness. Her blood pressure would rise from 130-140 systolic up to 210-220 systolic until the current of the stimulator was turned off.

This complication which was obviously due to spread of the electrode stimulation to the metallic body of the bullet fragment and echoing back to the spinal cord canal and to the cardiac plexus, and was mistaken for "infection" due to the surgical procedure. Obviously, there was no infection, and no infectious agent would grow from the serous fluid accumulation area. This was obviously a classical neurogenic inflammation(2). The stimulator was removed, replaced and the electrodes were repositioned for quite a few months, and all along the patient was kept on unnecessary and on large doses of antibiotics. An infectious disease consultant kept claiming that this was because of some sort of infectious agent even though nothing could be grown on culture.

The patient continued to run a temperature of 101.6-102.4 °F every time the SCS was on.

The temperature would go back to 99- 100 °F after the SCS was turned off. As soon as the stimulator was turned off, the tachycardia and hypertension would partially subside, but the stress of the SCS electrical stimulation would leave the patient with a baseline hypertension significant enough that she had to be on two different types of alpha blocker and calcium channel blocker medications.

The doctors who were treating her did not understand that the sympathetic system has three main functions. (i). Control of vital signs, in this case in the form of hypertension and tachycardia. (ii). Modulation of the body temperature, in this case a significant degree of fever. (iii). Modulation of the immune system which is the main domain of the sympathetic system function (2). I also discussed all of these phenomena in the book that I wrote in 1993 titled *Chronic Pain: Reflex Sympathetic Dystrophy, Prevention and Management*, published by CRC Press in Boca Raton, Florida(4).

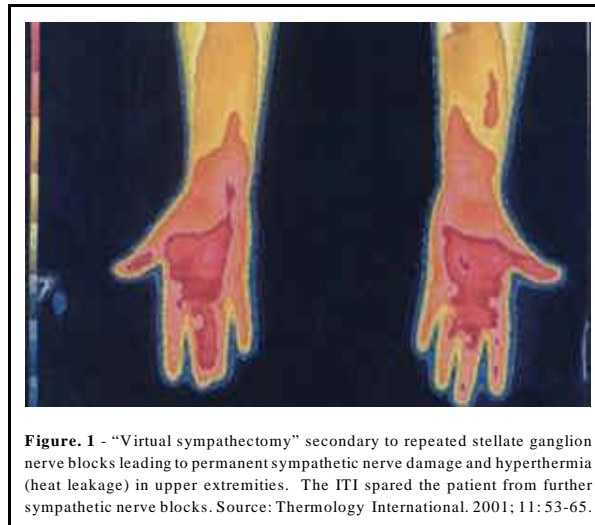
The patient received treatment of IV Mannitol for the problem of neuro-inflammation and water retention, and that eliminated the neuro-inflammation and the areas of inflammation that were mistaken for abscesses.

## TREATMENT

The main goal of treatment for CRPS is reversal of the course, amelioration of suffering, return to work if at all possible, avoiding surgical procedures such as SCS and amputation, and improvement of quality of life. The key to success is early diagnosis and early assertive treatment. Lack of proper understanding and proper diagnosis leads to improper treatment with poor outcome. There is a desperate need for future research in the treatment of CRPS. Delay in diagnosis is a factor in therapeutic failure. According to Poplawski, et al, treatment, and its results, are hampered by delay in diagnosis (5). Early diagnosis (up to 2 years) is essential for achieving the goal of successful treatment results. Simple monotherapy with only nerve block, only Gabapentin, or otherwise, is not sufficient for management of CRPS. Treatment should be multidisciplinary and simultaneous: effective analgesia, proper antidepressants to prevent pain and insomnia, physiotherapy, nerve blocks, proper diet, when indicated channel blockers, and anticonvulsant therapy should be applied early and simultaneously. Administration of piece-meal, minimal treatments is apt to fail (2).

The use of addicting drugs should be replaced with the treatment of choice for chronic pain in the form of newer-generation antidepressants. Trazodone is the treatment of choice to replace the tranquilizers and sleeping pills. It provides normal sleep, as well as prevention of chronic pain. The patient can be detoxified quickly and easily by discontinuation of the narcotics and replacement with nonaddicting ones, such as Buprenorphine (which is an opiate agonist-antagonist, it is a strong analgesic without causing dysphoria, or dependence), and Stadol. The use of muscle relaxant, Baclofen, which selectively works on the spinal cord, counteracts the spasm, clumsiness and tremor.

In our clinic we see such late stage CRPS cases we have practically never had any use for sympathetic ganglion blocks. We have learned that after several months and after repeated sympathetic ganglion blocks, the patient does not respond to any further ganglion blocks. We have published a number of articles regarding CRPS and they show that with the help of Infrared Thermal Imaging (ITI) we can identify which patients have had “virtual sympathectomy” due to repetitive sympathetic ganglion blocks (2,6,7,8) (Figure 1). Such patients obviously should be spared from the trauma of sympathetic ganglion blocks. Instead, the blocks we use are caudal blocks, cervical and lumbar epidural blocks containing Depo-Medrol®, paravertebral blocks, regional blocks, plexus blocks, etc.



## RESULTS

In our clinic we do not insert SCS, and all the cases that we have seen had their SCS implanted in other centers. We receive the late stage CRPS patients who have failed to respond to the multiplicity of different types of treatments for CRPS. So, our statistics are eschewed, toward more severe and more complicated patients.

When the patient is referred to our clinic (more than 80% of them are from other states, Canada, and Europe), they usually arrive on a Sunday and are treated for an average of 1-2 weeks before they return home. We have done a study to estimate the average length of time the patient has to stay in town before they are released to go back home.

What determines how many days the patient should stay before the patient can leave depends on how many days it takes to provide the patient with the maximum pain relief. Below are the results of this study (Table I).

<b>Table I. Average Course of Treatment</b>	
Course of Treatment	Duration of Treatment
1. No ice, no surgery	3.8 Days
2. Ice, no surgery	5.9 Days
3. Surgery	
3A. Single Procedure	
Sympathectomy	9.2 Days
Cryosurgery	14.5 Days
Rotator Cuff Surgery	12.8 Days
Spinal Cord Stimulator (SCS) Surgery	11.2 Days
Amputation Surgery	18 Days
3B. Multiple Procedures	
e.g.: Spinal Cord Stimulator (SCS) Surgery and Carpal Tunnel Surgery	16.1Days

**COMPLICATIONS OF SPINAL CORD STIMULATOR (SCS) IN CRPS**

As the condition of CRPS becomes chronic, the SCS can lead to spread of pain from the original site to other parts of the body (1,2).

This foreign body can cause disturbance of the immune system resulting in skin rash, dermatitis, skin lesions, and allergic reactions to SCS (1,3).

In rare cases, there are other complications noted with SCS application. These complications consist of the following:

(i). Epidural abscess or blood clots.

(ii). In occasional cases, the sensitization of the spinal cord by the SCS causes spinal cord sensitization in the form of myoclonic akinetic seizures(2). This sensitization is due to prolonged electrical stimulation causing exhaustion of the inhibitory nerve cells. Treatment with Klonopin®, and removal of the SCS prevents the sensitization.

Such attacks of myoclonic seizures originating from the spinal cord due to the spinal cord sensitization are not limited to the SCS. They are also seen in other spinal procedures(9). The diagnosis of spinal cord originated myoclonic seizures is quite difficult, and usually these patients are labeled as "functional" or "hysterical." Such patients respond very nicely to treatment with Klonopin®, brand name rather than generic.

The removal of SCS, as well as multidisciplinary treatments, aiming at desensitizing the spinal cord, help this condition.

Another problem with the SCS is the tendency for electrode movement due to improper anchoring, and the necessity for the surgeon try to correct the position of the SCS. Every operation is going to be another new source of CRPS pain.

SCS can also cause disturbance of plasticity and causes rapid acceleration and deterioration of CRPS to later stages of the disease. Another complication of SCS treatment is the fact that it stimulates the sensory neuropathic pain fibers in the spinal canal facilitating the spread of the disease to other extremities.

In the rare and severe cases of spinal cord sensitization, the patient may develop myoclonic jerks, and urgency, frequency, and even incontinence of urine, secondary to SCS irritating the urinary bladder and interstitial cystitis.

## **DISCUSSION**

In regards to the more common somesthetic pain such as FBS or FNS, we have found that SCS to be quite helpful and effective.

In contrast, in neuropathic pain, the beneficial effect of SCS may be short lived as little as a few hours or as long as several months. On the average, due to the late stage CRPS, 14% cannot tolerate the foreign body of SCS and the only way the SCS is kept in their body is by increasing the dosage of narcotics or using an additional narcotic to help the patient tolerate the foreign body. The common example is adding MS Contin and MSIR together or Methadone and MSIR together. Even then, the patient continues to have pain and discomfort and complains about the SCS, but that is blamed as a pre-existing neuropathic pain.

Two percent (2%) of the SCS patients have had early (less than 24 hours) complications of the SCS causing vasoconstriction in the distribution of the spinal artery branches resulting in temporary paraparesis. In one case the stimulator was not removed or repositioned, and as a result the patient became permanently paralyzed.

Another complication is aggravation of spinal cord sensitization due to the electrical stimulation. This complication was noted in 19% of the patients. The spinal cord sensitization is a relatively common late complication of CRPS with or without SCS treatment. It is manifested by attacks of myelogenic myoclonic jerks, as well as myelogenic akinetic attacks. These akinetic attacks usually go undiagnosed because of the fact that the patient already has poor balance and a tendency for falling in late stage CRPS, and as a result the akinetic seizures are over looked or mistaken for the chronic complication of poor balance in these patients. Akinetic seizures are quite stereotypical, and are easily diagnosed by epileptologists due to its distinct clinical picture. This is manifested by the patient suddenly and briefly (one second or more) losing the truncal muscle tonus and suddenly falling without any warning. The attacks may be quite brief lasting for a few seconds to the point that the patient can catch their balance, or may be longer and the patient may fall. The myoclonic and akinetic seizures are a common complication of spinal cord and brain stem dysfunction secondary to chronic epilepsy, or even viral infections. It is not easily diagnosed by people who don't have experience in epileptology.

The 19% of cases that have had akinetic seizures were in contrast to 3% incidence in the chronic CRPS patients who had not been treated with SCS.

ITI findings in patients that were treated with SCS showed no consistent vasodilation and hypothermic effect by SCS treatment. Clinically, SCS may relieve the pain within the first few weeks or months of implantation. With the passage of time, the pain and associated vasomotor response recur. This is simply another example of dysfunctional sympathetic system in CRPS (4,10). In our study of 44 SCS implantations for CRPS pain, versus 42 SCS implantation for FBS, the pain relief for CRPS patients was from five days to four months. In contrast, in FBS there was a tendency for mild and partial pain relief lasting up to 18 months. Other researchers have tried ITI on SCS treated patients with similar results (11,12).

## **SUMMARY AND CONCLUSION**

The use of spinal cord stimulators (SCS) is effective in treatment of somatic chronic pain (e.g., FBS and FNS) but they are not helpful in the management of treating CRPS patients.

Finally, in the patients who cannot tolerate the hardware of SCS, the scar of surgery for the SCS becomes a new and disabling source of neuropathic pain. The surgical area of insertion of the SCS becomes extremely hyperpathic, allodynic, and the pain overshadows the original pathology for which the SCS was necessitated. This has nothing to do with the quality of surgical procedure. I have had full training in neurosurgery and neurology, and I have found this hypersensitivity of the scar not being related to the surgical technique, but seems to be due to the hyperpathia and allodynia exacerbated by the electrical stimulation of the SCS.

The latter complication is so severe that when the patients are referred to us for treatment of late stage CRPS, first we request that the SCS be removed before we can make any progress with pain management.

No single physician is smart and potent enough to treat CRPS. Successful treatment requires teamwork of physical medicine, anesthesiology, and neuropharmacology physicians. The keys to successful treatment in CRPS are early diagnosis, early mobilization and extensive physical therapy, and early detoxification of the patient from addicting narcotics, alcohol, addicting tranquilizers and avoiding unnecessary surgical procedures such as SCS and amputation.

My ulterior motive in writing this paper is to help educate the patients and doctors in regard to these procedures. It is for the welfare of the patients and as importantly it is a preventive medicine measure to avoid wasted expense and further damage to the body.

## REFERENCES

1. McKenna KE and McCleane G: Dermatitis induced by spinal cord stimulator implant. *Contact Dermatitis*. 1999; 41: 229.
2. Hooshmand H, and Hashmi H: Complex regional pain syndrome (CRPS, RSDS) diagnosis and therapy. A review of 824 patients. *Pain Digest* 1999; 9: 1-24.
3. Ochani TD, Almirante J, Siddiqui A, et al: Allergic reaction to spinal cord stimulator. *Clin J Pain*. 2000; 16; 178-180.
4. Hooshmand H: *Chronic Pain: Reflex Sympathetic Dystrophy: Prevention and Management*. CRC Press, Boca Raton FL. 1993.
5. Poplawski ZJ, Wiley AM, Murray JF: Post traumatic dystrophy of the extremities. *J Bone Joint Surg [Am]*. 1983; 65:642-655.
6. Hooshmand H: Is thermal imaging of any use in pain management? *Pain Digest* 1998; 8:166-170.
7. Hooshmand H, Hashmi M, Phillips EM: Infrared thermal imaging as a tool in pain management - An 11 year study, Part I of II. *Thermology International* 2001; 11: 53-65.
8. Hooshmand, H., Hashmi, M., Phillips, E.M.: Infrared Thermal Imaging As A Tool In Pain Management - An 11 Year study, Part II: Clinical Applications, *Thermology International* 2001; 11: 1-13.
9. Rosenblum, JA: Spinal abdominal myoclonus. *The Neurologist*. 1996; 2: 784-787.
10. Birklein F, Riedl B, Claus D, et al: "Pattern of autonomic dysfunction in time course of complex regional pain syndrome." *Clinical Autonomic Research* 1998; 8: 79-85.
11. Devulder J, Dumoulin K, De Laat M, et al: Infra-red thermographic evaluation of spinal cord electrostimulation in patients with chronic pain after failed back surgery. *Br J Neurosurg* 1996; 10: 379-383.
12. Pawl RP: Thermography in the diagnosis of low back pain. *Neurosurg Clin N Am* 1991; 2: 839-850.

